

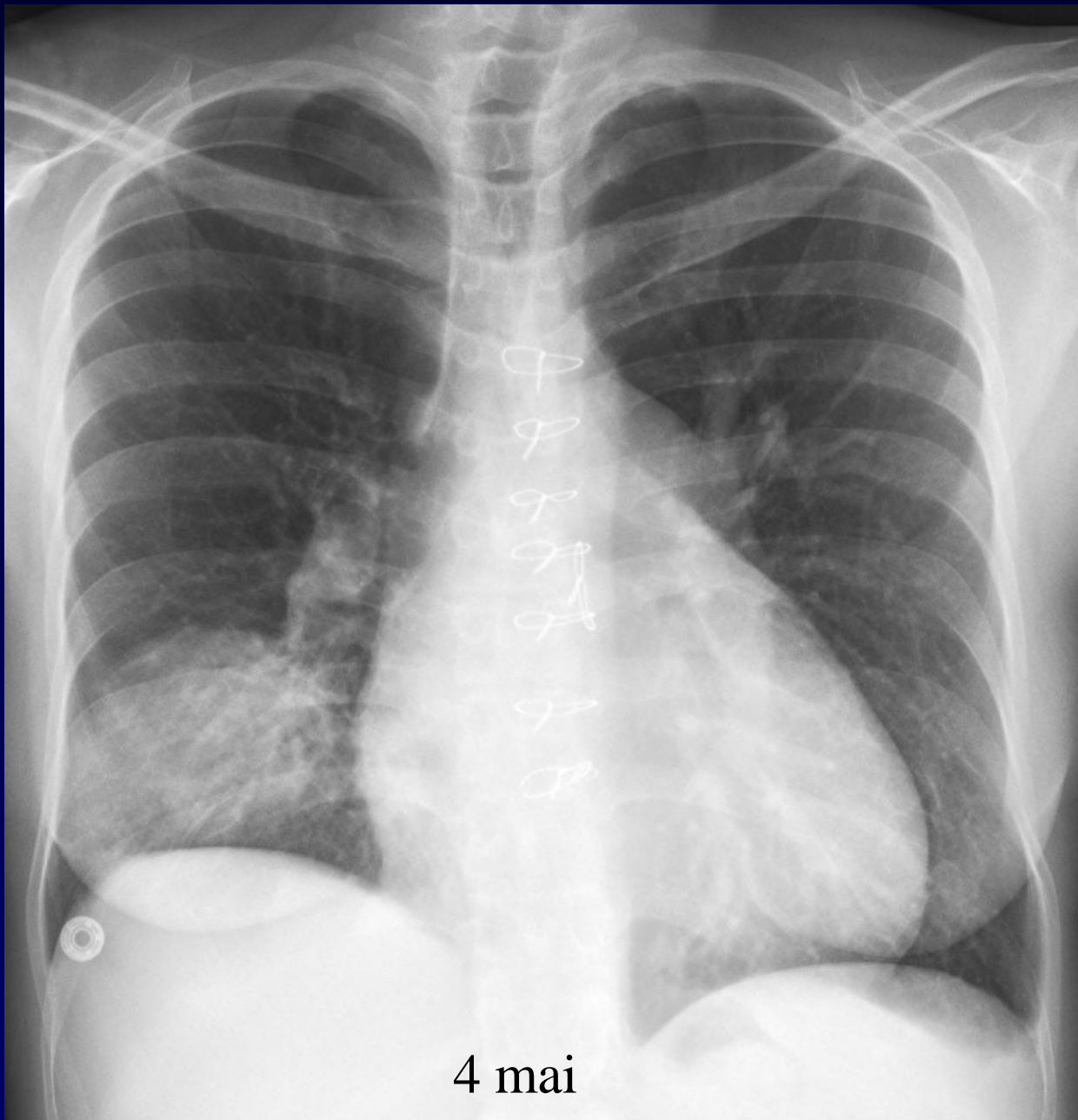


MP Debray

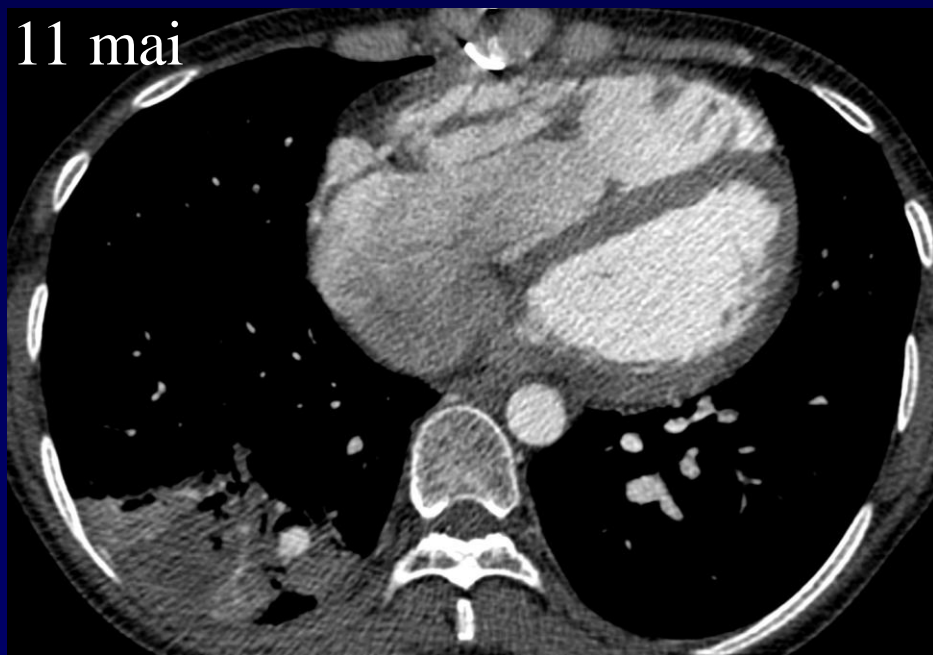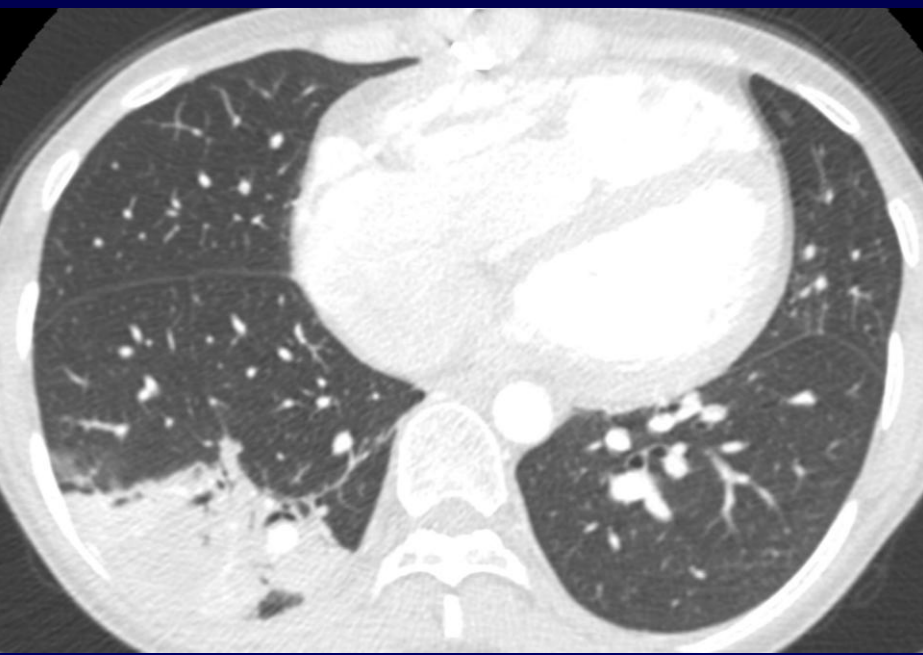
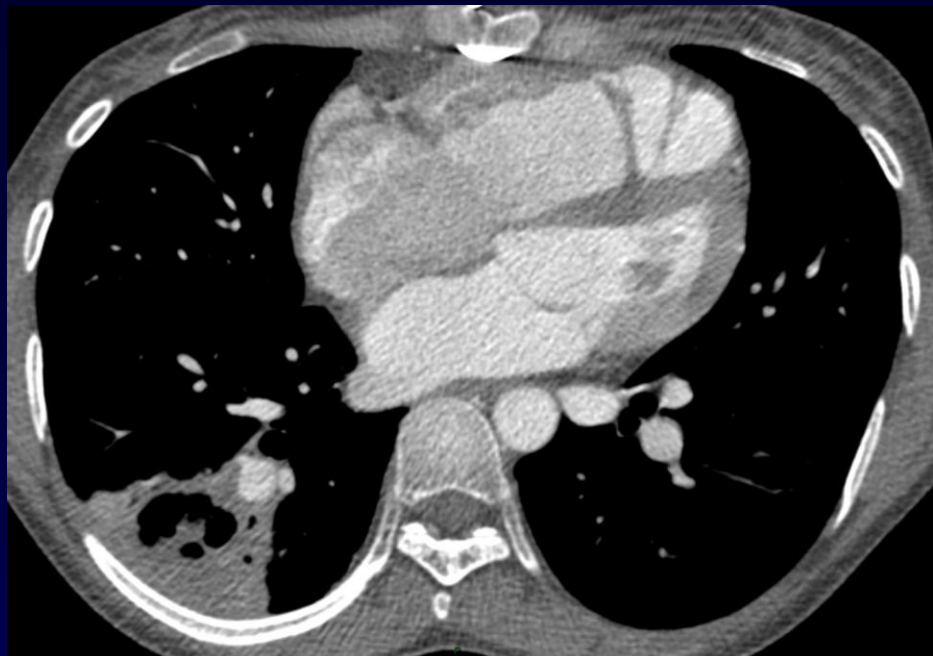
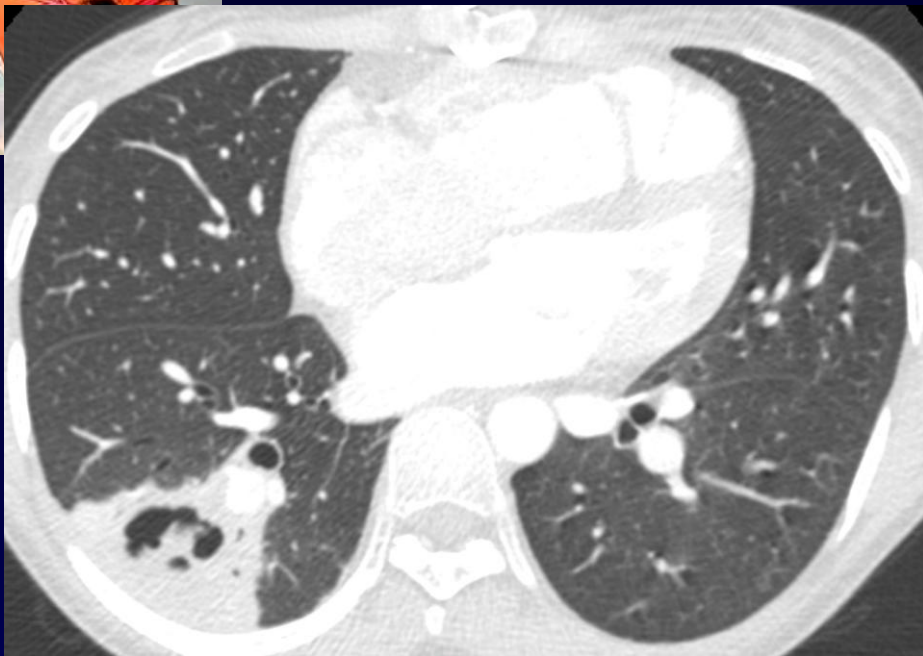
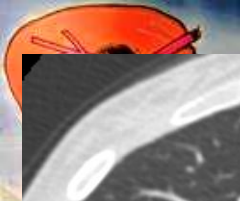
Femme, 32 ans

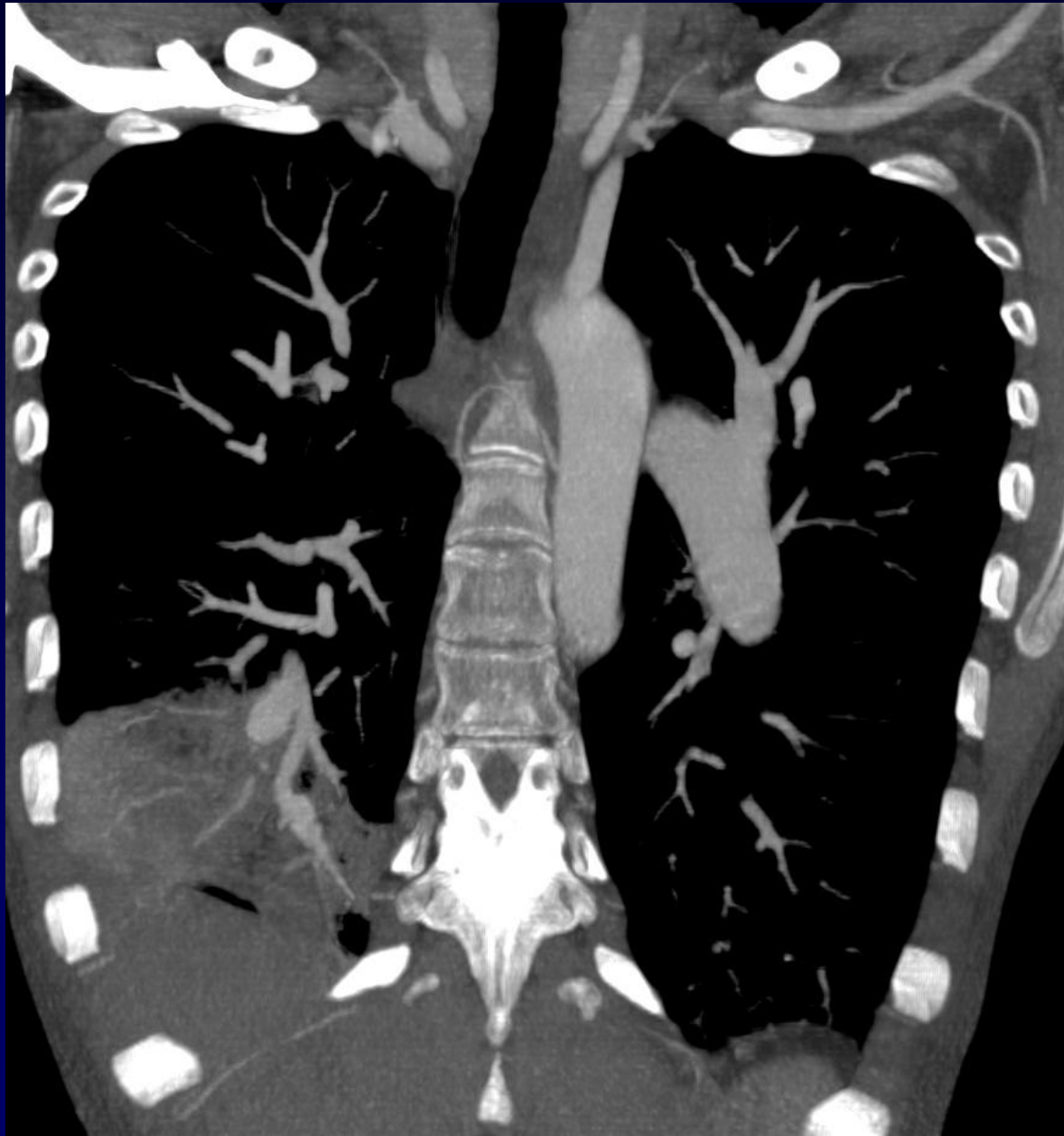Fièvre paroxystique

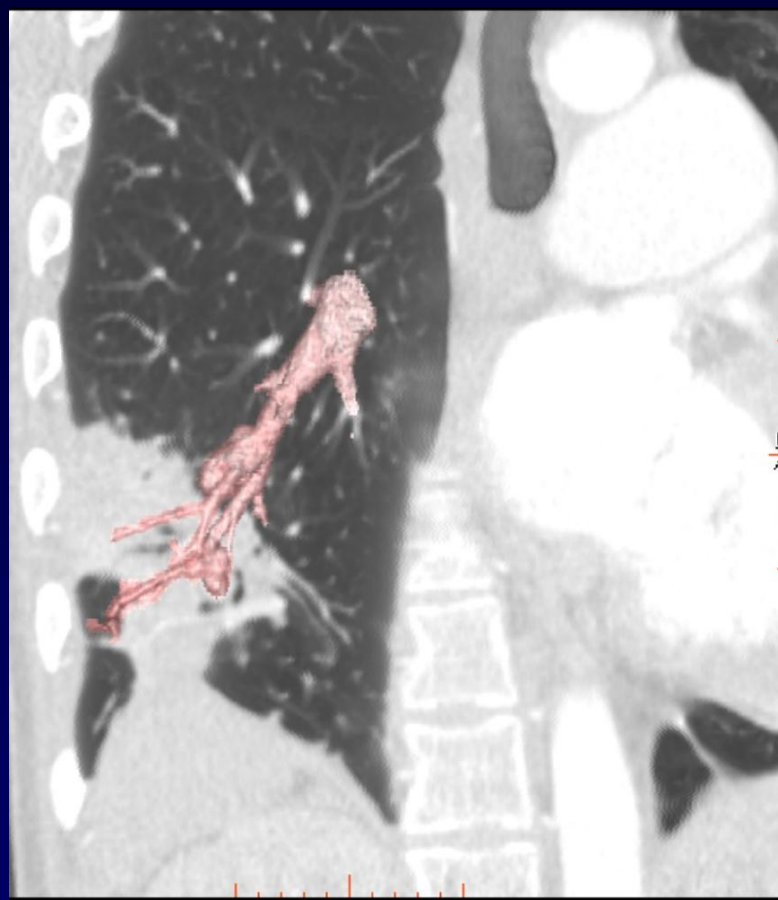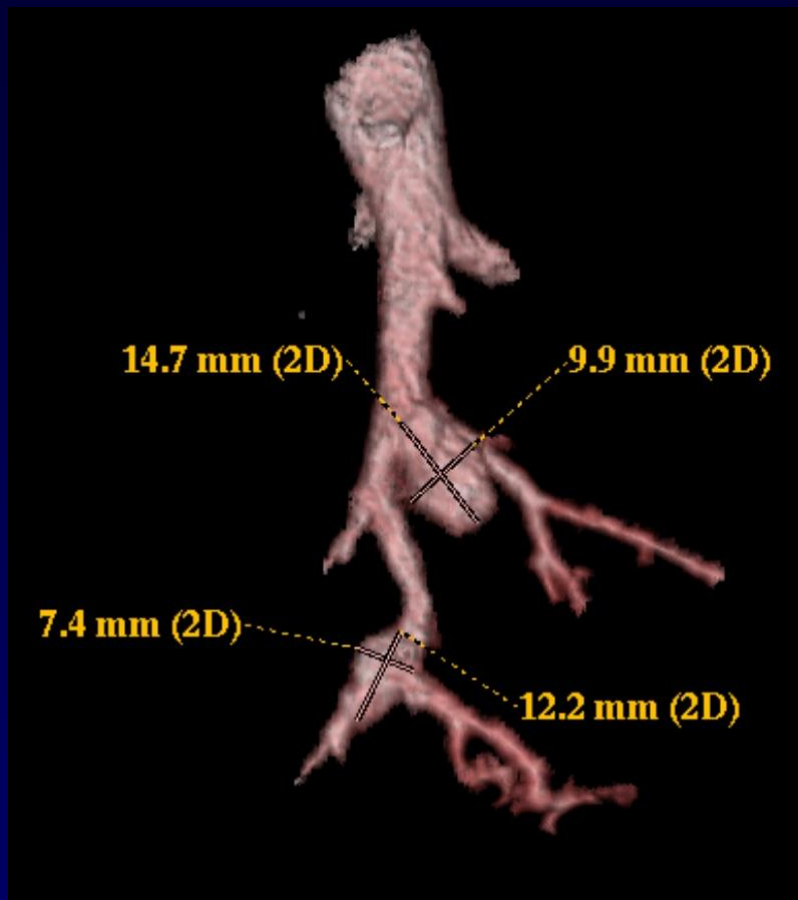
ATCD de greffe de la valve pulmonaire sur
sténose valvulaire congénitale il y a plusieurs
années

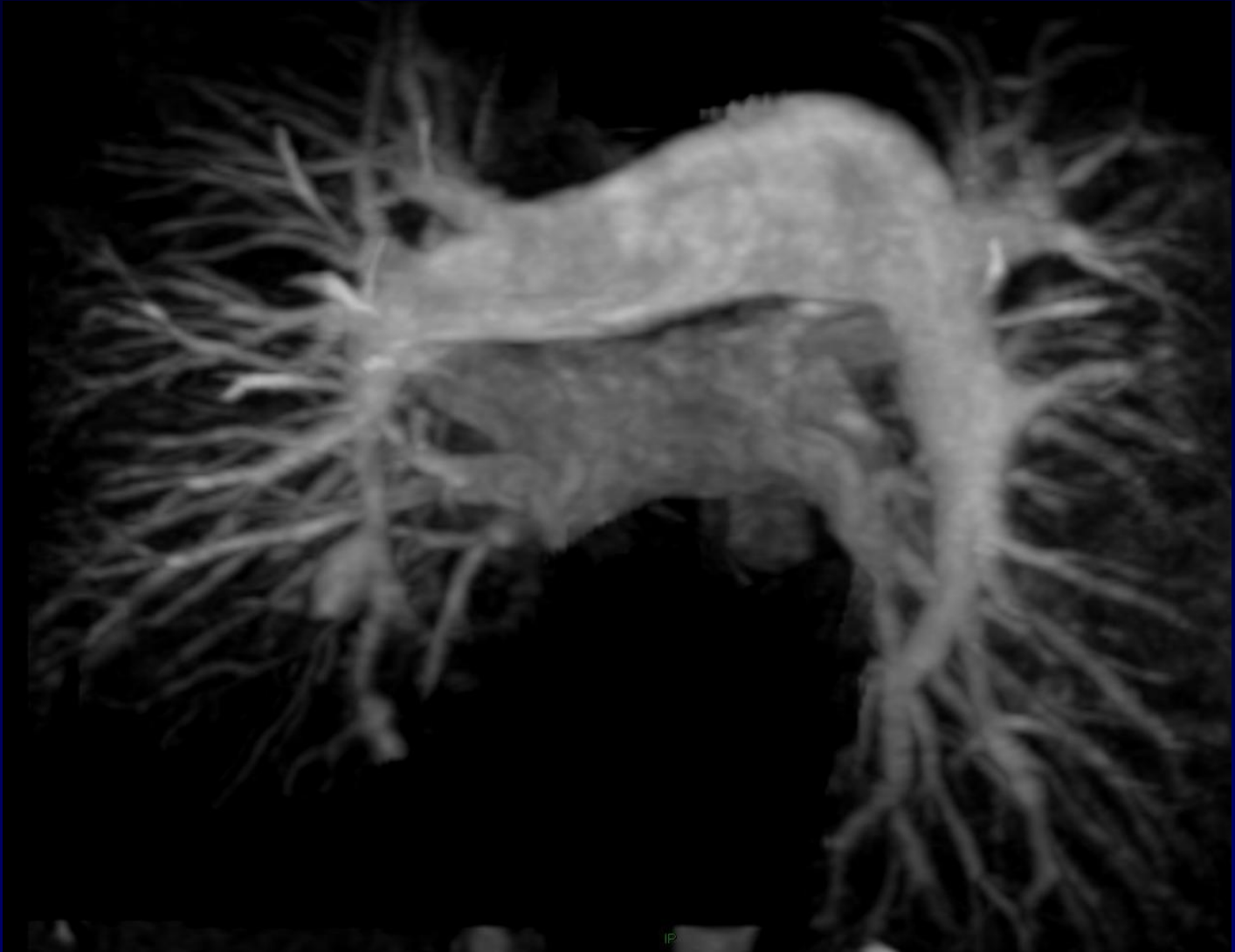

4 mai

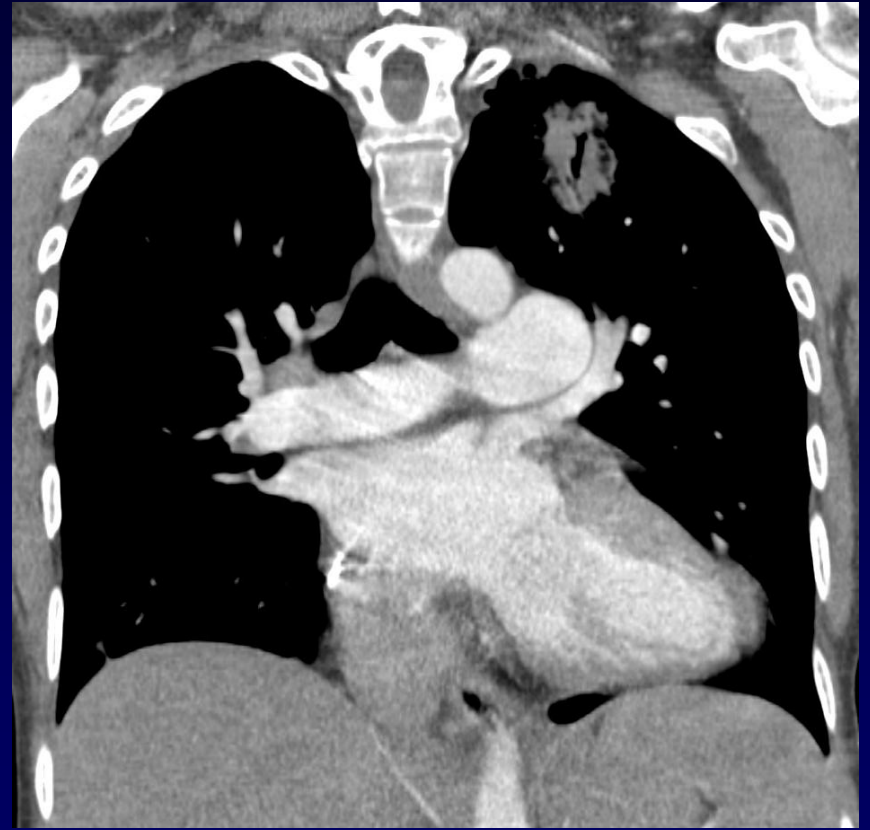
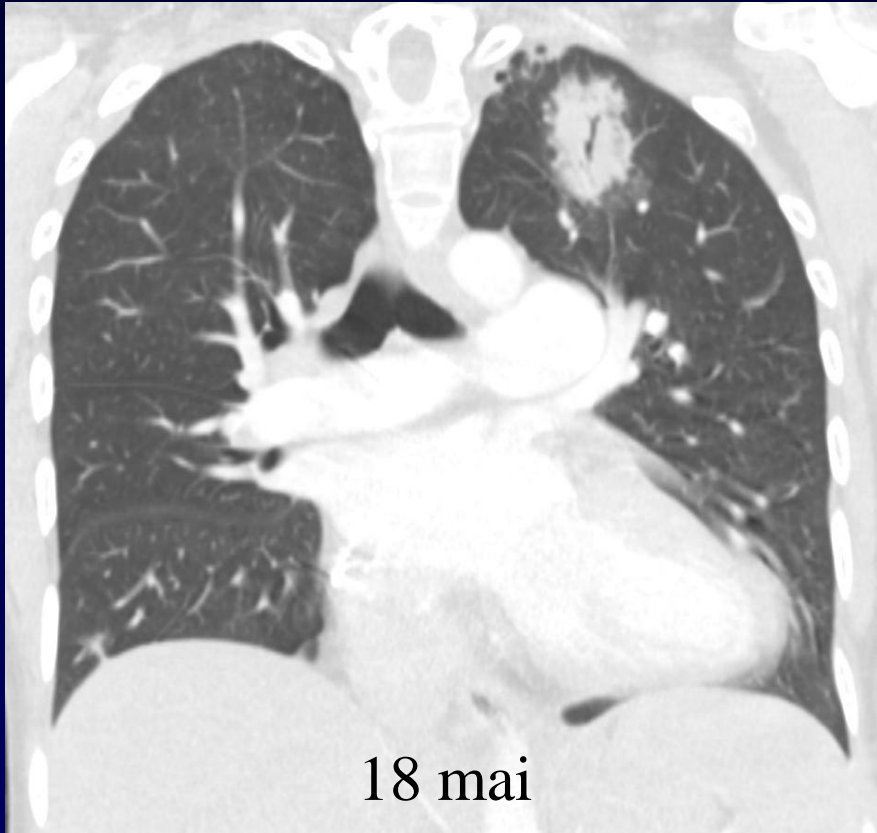


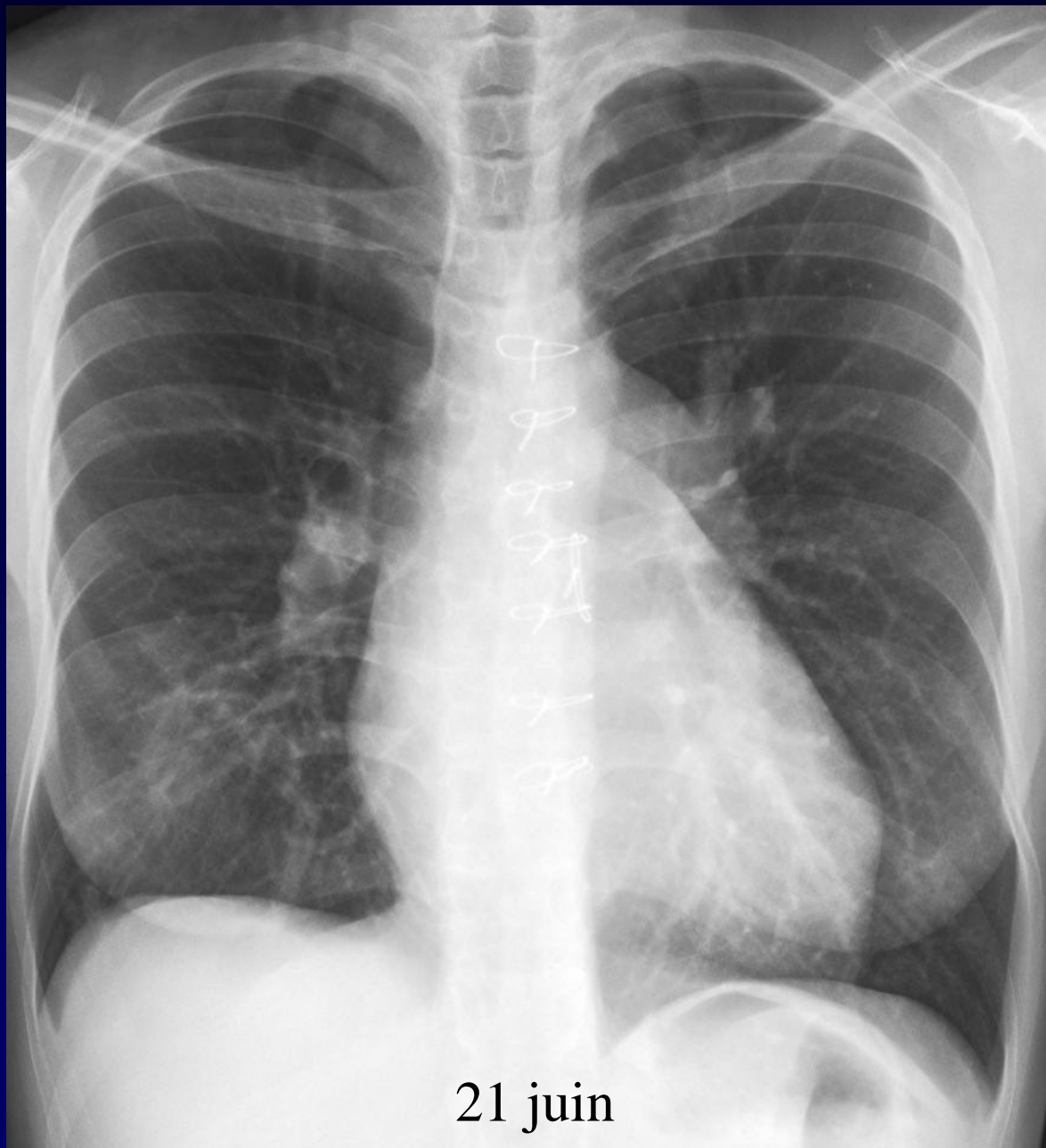




IP

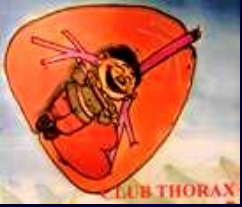



21 juin



Diagnostic ?



Diagnostic

Anévrysmes mycotiques artériels pulmonaires sur endocardite droite

- Hémoculture positive à *Aggregatibacter Actinomycetemcomitans*
- Végétation sur la valve pulmonaire
- Diminution de taille des images anévrysmales à l'angioMR sous antibiothérapie prolongée